



## The AP chest X-ray

Indications and technical considerations

---

---

---

---

---

---

### What will I gain from this video?

At the end of the video, you will know when to order an AP chest X-ray and why.

---

---

---

---

---

---

### When to order a AP chest X-ray?

- Patient bedridden
- Cannot have PA and LAT

---

---

---

---

---

---

**Limitations: technical**

- Poor inspiration
- More artifacts
- Exposure difficulties

---

---

---

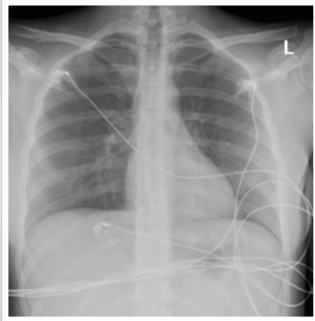
---

---

---

**Limitations:  
technical**

Good quality example



---

---

---

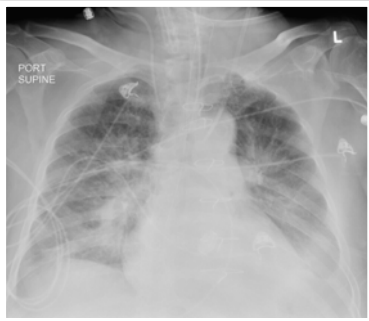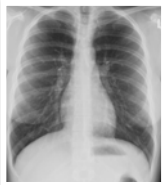---

---

---

**Limitations:  
technical**

Supine



---

---

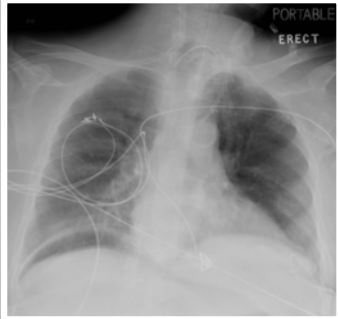
---

---

---

---

**Limitations:  
technical**



---

---

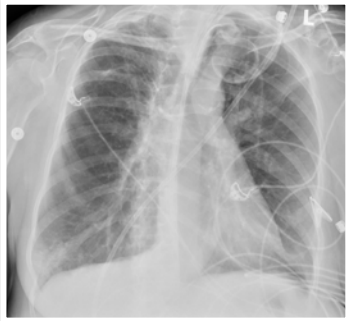---

---

---

---

**Limitations:  
technical**



---

---

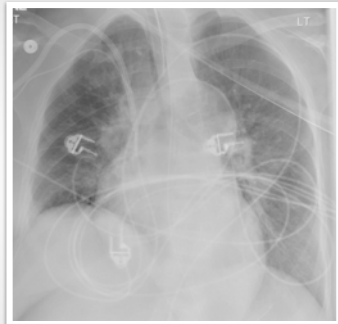---

---

---

---

**Limitations:  
technical**



---

---

---

---

---

---

**Limitations: anatomical**

- Cardiac enlargement—magnification
- Widening of mediastinum—magnification
- Prominent vessels—supine

---

---

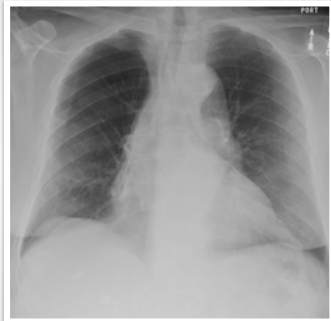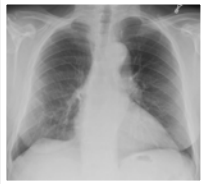
---

---

---

---

**Limitations:  
anatomical**



---

---

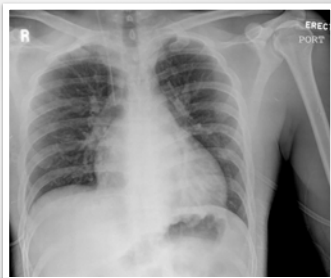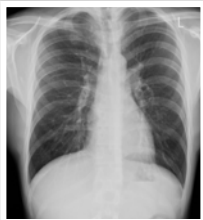---

---

---

---

**Limitations:  
anatomical**



---

---

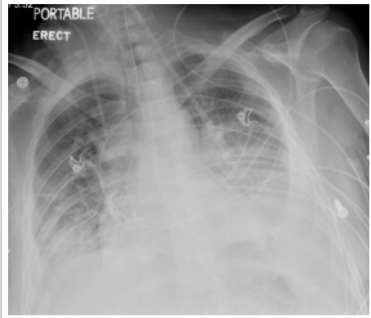
---

---

---

---

**Example**



---

---

---

---

---

---

Difficult to obtain high quality examination.

Differences between PA and AP:

Cardiac enlargement—magnification.

Widening of mediastinum—magnification.

Prominent vessels—supine.

Better vs. worse? Complications?

---

---

---

---

---

---